



Summary Feedback

(Combined feedback broadcasted multiple time this week)

PRE-RECORDED: Basildon FRCR 2B 'A to Zee' Course 2020

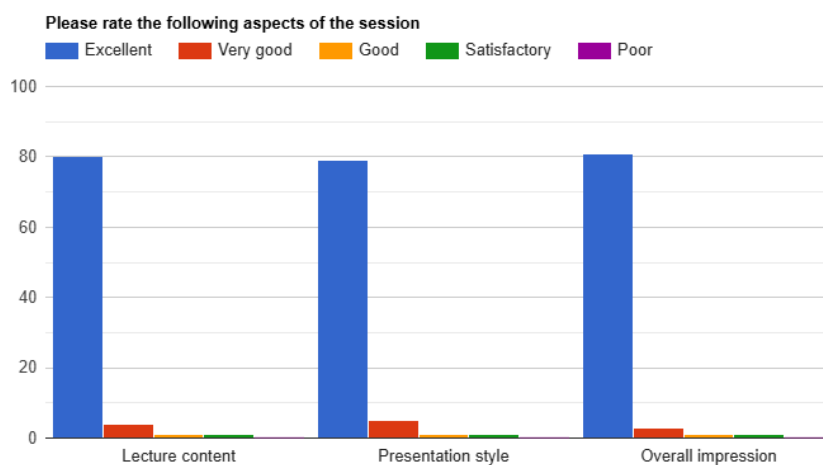
Session 17/38

Paediatrics for FRCR Neonatal and Paediatric Chest and Cardiac Pathologies (26th & 27th July 2025)

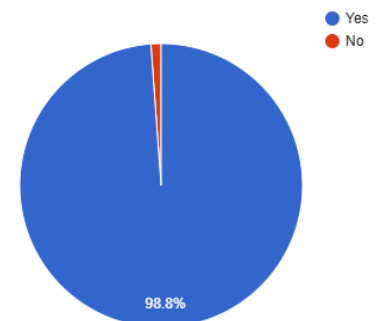
Lecturer: Divya Vaid & Mahwish Arshad

Summary Points:

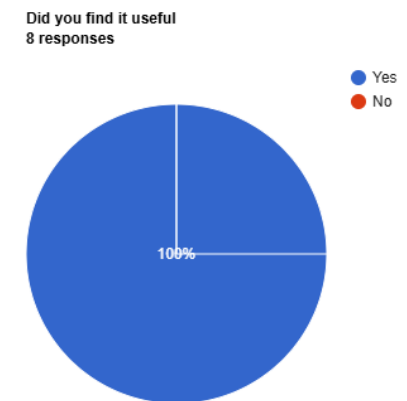
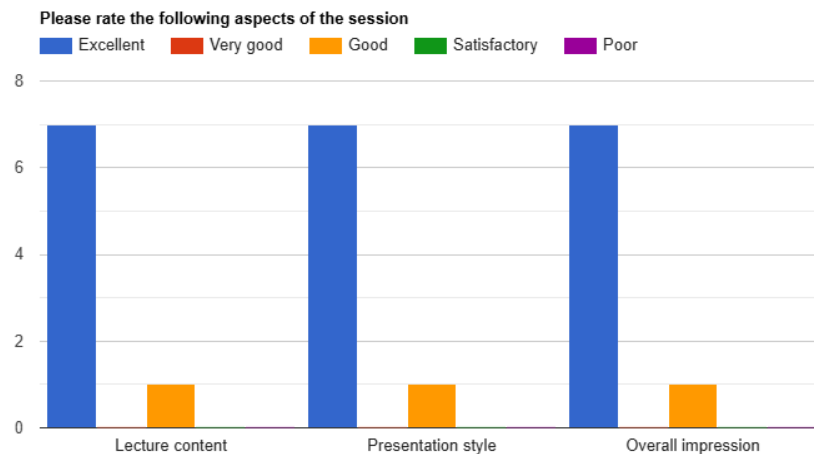
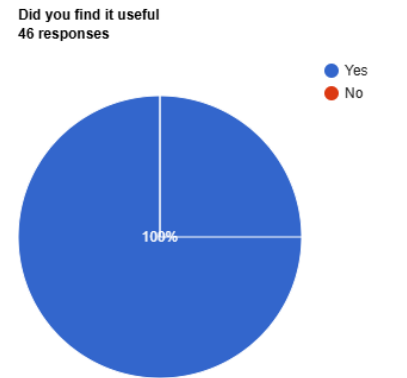
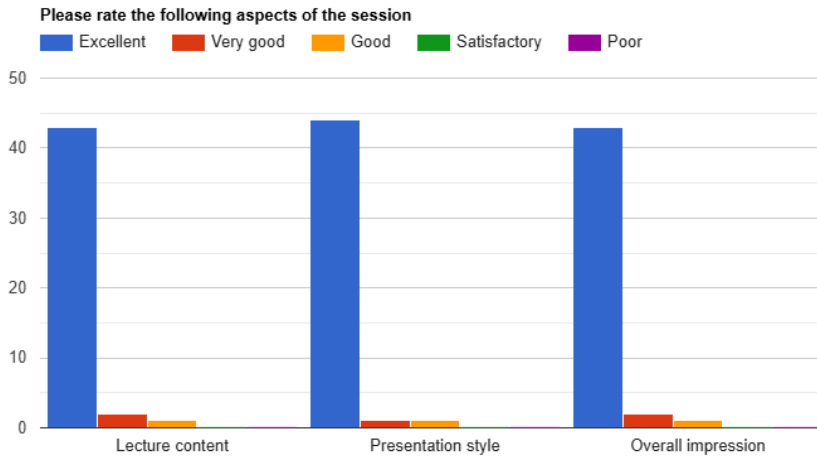
- Total Attendees: 384 from 34 Countries (Algeria, Australia, Bangladesh, Dominica, Egypt, Ghana, India, Indonesia, Iran, Iraq, Ireland, Kenya, Libya, Malaysia, Namibia, Nigeria, Norway, Oman, Pakistan, Qatar, Saudi Arabia, Singapore, South Africa, Sri Lanka, Sudan, Swaziland, Thailand, Trinidad and Tobago, Türkiye, UAE, Uganda, UK, Yemen, Zimbabwe).
- Total duration: 3 hours (each session broadcasted thrice during the week)
- Total feedback received from 140 participants, from three different broadcasts



Did you find it useful
86 responses



Paediatrics for FRCR: Neonatal and Paediatric Chest and Cardiac Pathologies

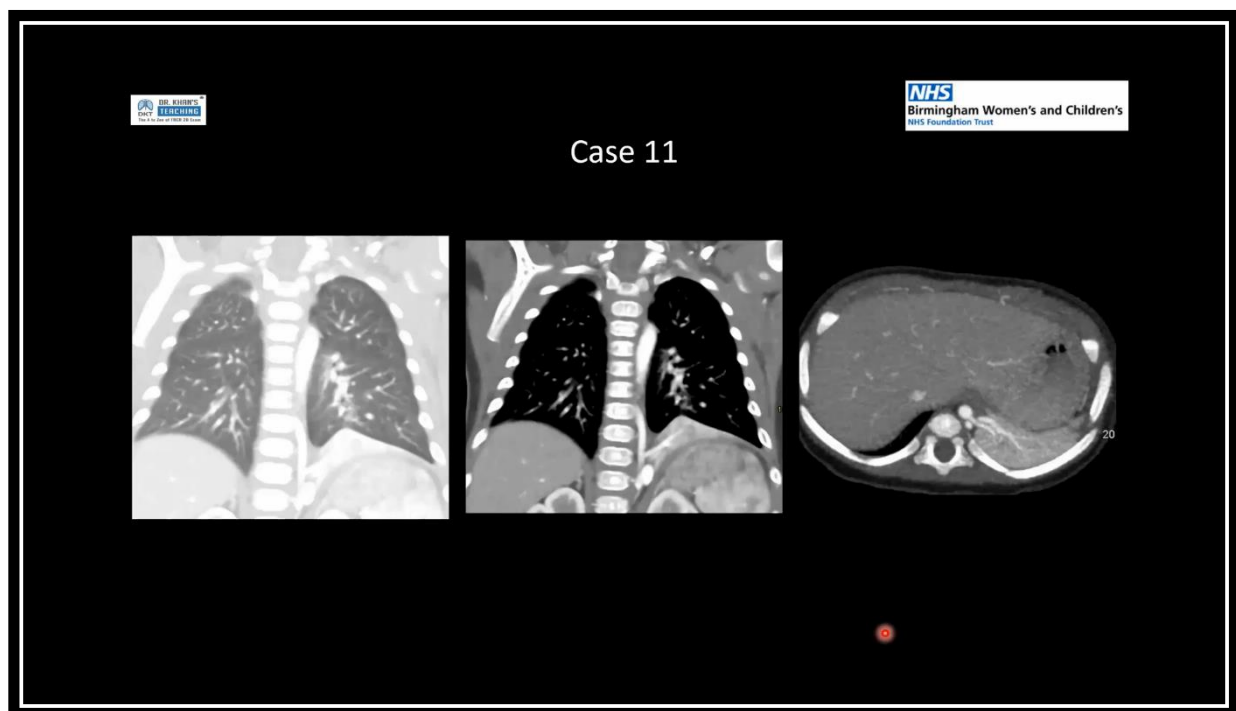


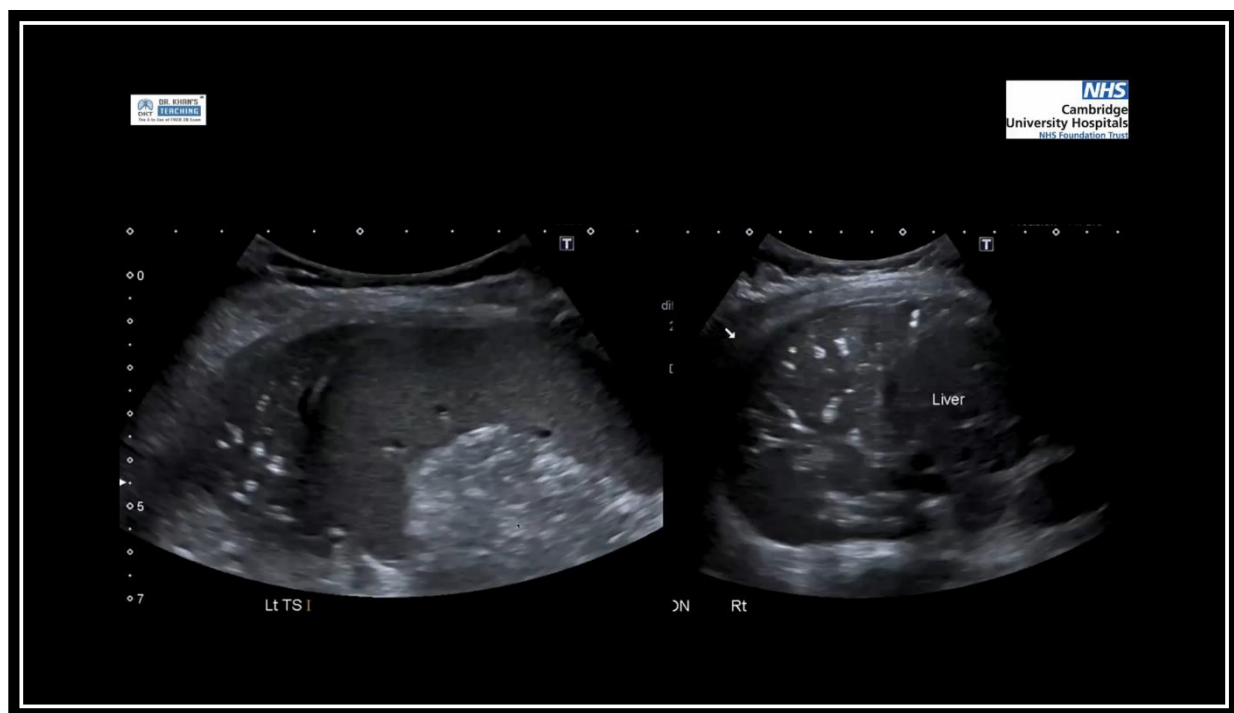
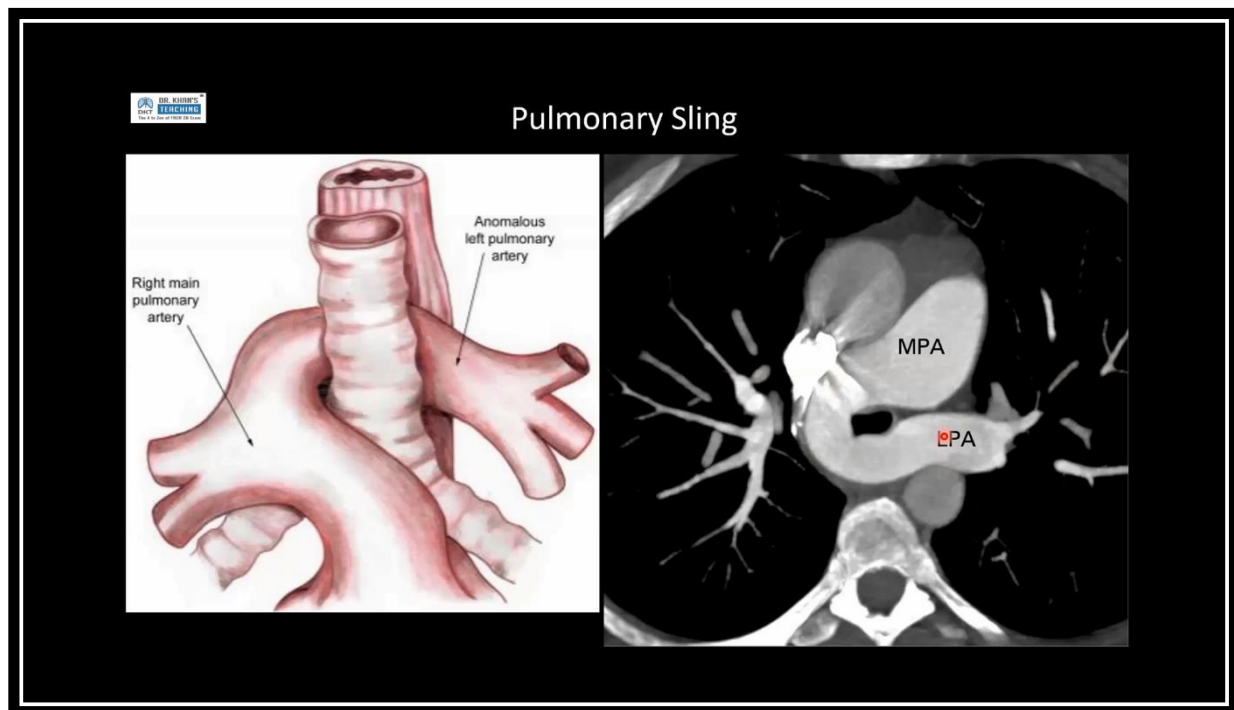
Testimonials

- Another amazing elaborative teaching session on pediatric chest imaging, giving an exposure on lots of abnormal chest radiographs & their interpretations (India).
- Varied case presentation and interactive discussion on differential diagnosis as well as the management (Singapore).
- The neonatal & pediatric chest and cardiac pathologies and the viva cases were really useful (UK).
- A very important topic was taught beautifully in detail (UAE).
- Discussion of findings on the radiograph was very helpful (India).
- Everything was useful, especially the difference in chest lines (Sri Lanka).
- The cases were great! The approach was exceptionally taught (Zimbabwe).
- Visual content with great explanation were useful (Trinidad & Tobago).
- Dr. Khan's Teaching is a blessing for me (Pakistan).
- I liked the range of cases - both breaking down the basics, and review of more unusual diagnoses (UK).

- The lecturers, the participants and the wonderful cases were very carefully selected (Yemen).
- Very informative session for pediatric imaging (Singapore).
- Interesting cases, a quick reminder and constructive feedback (Algeria).
- I liked the teaching session and the case description (Nigeria).
- Nice cases (Pakistan).
- Excellent cases and explanation (UK).
- Best cases (Pakistan).
- Excellent teaching session (Nigeria).
- Impressive (South Africa).
- It was perfect (UAE).
- Well organized. Good coverage of opacified hemithorax, CDH, pneumothorax, CLE and CCAM (UK).
- It's all useful (UAE).
- Excellent paediatrics chest session (Saudi Arabia).
- Amazing variety of cases (UK).
- Useful for both clinical and exam purposes (Singapore).
- The guidelines given by the lecturer were really useful (Singapore).
- Excellent content and explanation (India).
- It was perfect (UAE).
- Nice cases (Sudan).
- Lung is welcome all the time - just amazing always!! (UK).
- Good, organized lecturer (UK).
- All aspects are perfect (UK).
- Very useful (UK).
- Wonderful session (Pakistan).
- Very insightful (UK).
- Very educative (Nigeria).
- Thank you to presenter and team (UK).
- Good learning experience (India).
- Excellent lecture (UK).
- Nice. Keep it up (Pakistan).
- Good coverage of the main paediatric chest conditions (UK).
- Excellent thanks for the help (UK).
- Great lecture! (Zimbabwe).
- Very good and useful (Trinidad & Tobago).
- Excellent teaching session (Nigeria).
- Very enlightening (UK).
- Very nice lesson (Sudan).
- Case presentation and discussion was the most helpful part (India).
- The explanation offered was brilliant (Pakistan).
- Amazing Lecture content (UK).
- Difficult but useful paediatrics CXR cases (UK).
- Very good cases (UAE).
- Excellent case discussion (Egypt).

- Amazing content and delivery (UK).
- One of the best sessions (Thailand).
- US images of lung very useful to revise the rest of cases also well chosen (UK).
- All the aspects were useful (UK).
- Excellent cases and explanation (Saudi Arabia).
- Amazing case discussion (India).
- Difficult topic explained very nicely. Thank you! (Pakistan).
- Excellent images and teaching points (Pakistan).
- Good coverage of how to approach paediatric/neonatal CXR (UK).
- It was very useful & valuable (Egypt).
- Beautiful explanations (Pakistan).
- Great cases (Libya).
- Could be more straightforward and organized (Türkiye).
- Excellent images and cases presentation (Pakistan).
- I liked the multiplicity of the cases (Iraq).
- Excellent cases (UK).
- The case selection was brilliant (Nigeria).
- Excellent chest imaging (Nigeria).
- I liked the vast array of cases and the teaching style (Nigeria).
- Excellent teaching (UK).





=====XX=====XX=====